

# Research letter

## Sweet-like syndrome and multiple COVID arm syndrome following COVID-19 vaccines: 'specific' patterns in a series of 192 patients

DOI: 10.1111/bjd.21692

DEAR EDITOR, For the past 2 years, the world has been facing a new viral pandemic caused by the SARS-CoV-2 coronavirus. So far, about 11 billion doses of COVID-19 vaccines have been administered globally, most of them being mRNA vaccines. While their overall good tolerance has been acknowledged, various delayed skin reactions, including large local reactions named 'COVID arm', have been reported in several countries.<sup>1-5</sup>

A nationwide survey-based study was conducted by the French Society of Dermatology to describe the clinical and histological features of delayed skin reactions following COVID-19 vaccines and to identify specific clinicopathological patterns. Between May and September 2021, French dermatologists reported delayed local-site or/and diffuse reactions. They were invited to choose the most suitable diagnosis in a list of previously published skin manifestations following COVID-19 vaccine,<sup>2</sup> or they could choose 'not applicable' and propose another diagnosis. Participants were invited to provide clinical pictures and histology reports. All cases were reviewed by the COVACSKIN steering committee to evaluate the diagnosis proposed for each patient or eventually reclassify it. The COVACSKIN study was approved by the Bordeaux University Hospital ethical committee (no. APP-2021-17).

We recorded 194 individual questionnaires corresponding to 192 patients (63% women, median age 54 years), among whom 171 received an mRNA vaccine. Delayed skin reactions mostly occurred after the first dose of vaccine, with a median delay of 2.6 days. About 91% had delayed diffuse cutaneous reactions, including 15.5% concomitantly presenting with a local-site reaction. Among the 176 cases of delayed diffuse cutaneous reactions, 66 were classified as 'not applicable'. In this category, we recorded seven acute generalized exanthematous pustulosis, two lupus, four bullous pemphigoid, seven psoriasis and psoriasis-like reactions, seven pityriasis rosea-like reactions, six lichen, six prurigo, three lichenoides pityriasis, two rosacea, two multiform erythema, one lymphoedema, one erythema nodosum and one cicatricial pemphigoid.

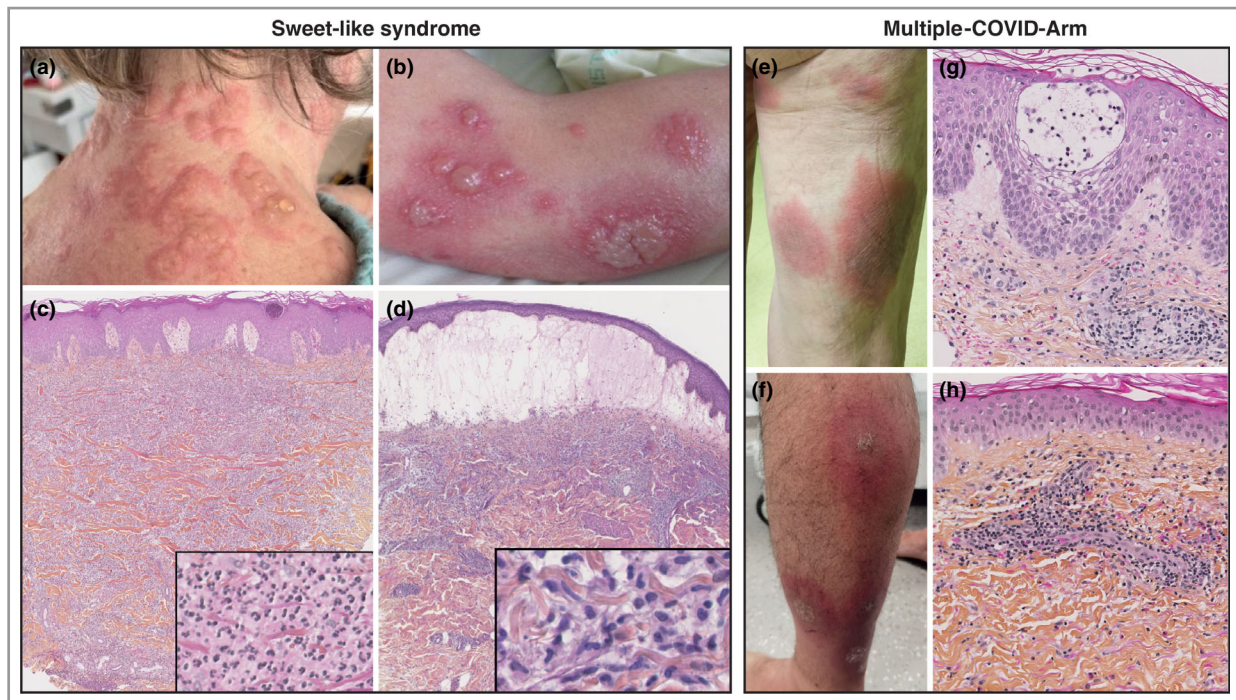
Aside from these, 17 cases presented with a pattern of inflammatory, oedematous and erythematous papules or plaques (Figure 1). For 13 of these cases, a histological examination was performed by three dermatopathologists

(M.-L.J., P.M., P.S.). A post hoc evaluation of the clinical and histological features led to the delineation of two specific subsets that shared a clinical presentation with inflammatory and oedematous papules and plaques.

The first presentation (seven patients) occurred with a median time to onset of 7 days and corresponded to erythematous and oedematous papules or plaques, sometimes developing vesiculation or bullae, and resembling Sweet syndrome. Therefore, this pattern was named 'Sweet-like syndrome' (Figure 1a, b). Only two patients had a classical Sweet syndrome histology showing a diffuse dermal neutrophilic infiltrate, while two had a dermal infiltrate of histiocyte-like immature myeloid cells compatible with histiocytoid Sweet syndrome (Figure 1c, d). Importantly Sweet-like syndrome induced by vaccines is not a contraindication to further vaccine injections. Of the seven patients in this subset, six had further injections and only one relapsed, although less severely, and two patients presented with different cutaneous reactions following the next injection.

The second presentation (five patients) occurred with a median time to onset of 2 days and displayed multiple, large and uniform oedematous plaques. As these plaques were highly reminiscent of the 'COVID arm' description,<sup>1,2,5,6</sup> we proposed to name it 'multiple COVID arm' (MCA) (Figure 1e, f). None of these patients had a typical COVID arm at the injection site. Histological analyses of these reactions revealed a perivascular and interstitial inflammatory infiltrate with eosinophils, consistent with a delayed-type hypersensitivity reaction (Figure 1g, h), similar to the histopathological features reported in COVID arm.<sup>6,7</sup> This peculiar clinicopathological presentation has never been described as a vaccine side-effect so far. The pathogenesis of MCA lesions is likely to be similar to that of COVID arm, resulting from delayed hypersensitivity to an immunogenic trigger, probably the COVID-19 vaccine.<sup>6</sup> Of these five patients, four had further injections and two relapsed.

Lastly, five patients had unique or multiple oedematous plaques that were not typical Sweet-like syndrome or MCA lesions. Skin biopsies had been performed for only two of them, respectively showing a dermal perivascular and periadnexal lymphocytic infiltrate resembling perniosis, and a vacuolar interface dermatitis. McMahon *et al.* have recently reported the histological features of 58 diffused skin reactions and revealed 13 different clinicopathological patterns.<sup>8</sup> Among these patterns, a spectrum of lesions displaying different degrees of spongiosis and interface changes was identified and named vaccine-related eruption of papules and plaques









**Figure 1** Sweet-like syndrome and multiple-COVID-arm reactions following COVID-19 vaccines. (a, b) Clinical pictures of Sweet-like syndrome lesions. (c) Skin biopsy displaying features of classical Sweet syndrome with papillary dermis oedema and a dense inflammatory infiltrate of mature neutrophils involving the whole dermis ( $\times 40$ , haematoxylin–erythrosine–safron). Inset: mature neutrophils ( $\times 340$ ). (d) Skin biopsy displaying histiocytoid Sweet syndrome with an intense bullous dermal oedema, and an underlying dense, bandlike, inflammatory infiltrate involving the superficial and mid-dermis ( $\times 25$ , haematoxylin–erythrosine–safron). Inset: mononuclear cells showing elongated nuclei and scant eosinophilic cytoplasm mimicking small histiocytes ( $\times 350$ ). (e, f) Clinical pictures of multiple-COVID-arm lesions. (g) Skin biopsy displaying spongiotic epidermal changes and a moderate perivascular and interstitial inflammatory infiltrate involving the superficial dermis ( $\times 200$ , haematoxylin–erythrosine–safron). (h) Skin biopsy showing dermal inflammatory infiltrate with perivascular lymphocytes and a few scattered eosinophils ( $\times 200$ , haematoxylin–erythrosine–safron).

(V-REPP).<sup>8</sup> While MCA lesions displayed some spongiosis, they were clinically distinct from V-REPP lesions, and so were ‘Sweet-like syndrome’ lesions.

In conclusion, we confirmed the broad diversity of delayed cutaneous reactions following COVID-19 vaccines. In addition, we report two specific clinical patterns of oedematous and inflammatory manifestations, including ‘Sweet-like syndrome’ and ‘multiple-COVID-arm’ lesions.

Acknowledgments are listed in [Appendix S1](#) (see Supporting Information).

Acknowledgement: Open access funding enabled and organized by ProjektDEAL.

Anne-Sophie Darrigade <sup>1,2</sup> Bénédicte Oulès,<sup>3,4</sup> Pierre Sohier,<sup>4,5</sup> Marie-Laure Jullie,<sup>6</sup> Philippe Moguelet,<sup>7</sup> Annick Barbaud,<sup>2,8</sup> Angèle Soria <sup>2,8</sup> Nicolas Vignier,<sup>9,10,11</sup> Bénédicte Lebrun-Vignes,<sup>2,12</sup> Paola Sanchez-Pena <sup>2,13</sup> Olivier Chosidow <sup>1,4,15,16</sup> Marie Beylot-Barry <sup>1,17</sup> Brigitte Milpied <sup>1,2</sup> Nicolas Dupin<sup>3,4,15</sup> and on behalf of the French Society of Dermatology

<sup>1</sup>Department of Dermatology, Saint-André Hospital, University Hospital of Bordeaux, Bordeaux, France; <sup>2</sup>FISARD, French Investigators for Skin Adverse Reactions to Drugs of the French Society of Dermatology, Paris, France; <sup>3</sup>Department of Dermatology, Cochin Hospital, AP-HP, Centre-Université Paris Cité, Paris, France; and <sup>4</sup>Cutaneous Biology Lab, Institut Cochin, INSERM U1016, Université Paris Cité, UMR, 8104, Paris, France  
Email: anne-sophie.darrigade@chu-bordeaux.fr

A full list of affiliations is available in [Appendix S2](#) (see Supporting Information).

A.-S.D. and B.O. contributed equally to this work.

M.B.-B., B.M. and N.D. contributed equally to this work.

## References

- Blumenthal KG, Freeman EE, Saff RR et al. Delayed large local reactions to mRNA-1273 vaccine against SARS-CoV-2. *N Engl J Med* 2021; **384**:1273–7.
- McMahon DE, Amerson E, Rosenbach M et al. Cutaneous reactions reported after Moderna and Pfizer COVID-19 vaccination: a registry-based study of 414 cases. *J Am Acad Dermatol* 2021; **85**:46–55.

- 3 Català A, Muñoz-Santos C, Galván-Casas C et al. Cutaneous reactions after SARS-CoV-2 vaccination: a cross-sectional Spanish nationwide study of 405 cases. *Br J Dermatol* 2022; **186**:142–52.
- 4 Grieco T, Maddalena P, Sernicola A et al. Cutaneous adverse reactions after COVID-19 vaccines in a cohort of 2,740 Italian subjects: an observational study. *Dermatol Ther* 2021; **34**:e15153.
- 5 Centers for Disease Control and Prevention. Allergic reactions after COVID-19 vaccination. Available at: <https://www.cdc.gov/coronavirus/2019-ncov/vaccines/safety/allergic-reaction.html> (last accessed 7 June 2022).
- 6 Kempf W, Kettelhack N, Kind F et al. 'COVID arm' – histological features of a delayed-type hypersensitivity reaction to Moderna mRNA-1273 SARS-CoV2 vaccine. *J Eur Acad Dermatol Venereol* 2021; **35**:e730–2.
- 7 Hoff N-P, Freise NF, Schmidt AG et al. Delayed skin reaction after mRNA-1273 vaccine against SARS-CoV-2: a rare clinical reaction. *Eur J Med Res* 2021; **26**:98.
- 8 McMahon DE, Kovarik CL, Damsky W et al. Clinical and pathologic correlation of cutaneous COVID-19 vaccine reactions

including V-REPP: a registry-based study. *J Am Acad Dermatol* 2022; **86**:113–21.

Funding sources: none.

Conflicts of interest: the authors declare they have no conflicts of interest.

Data availability: Data available on request from the authors.

## Supporting Information

Additional Supporting Information may be found in the online version of this article at the publisher's website:

**Appendix S1** Acknowledgments.

**Appendix S2** Full list of affiliations.