

Docetaxel-induced photo-recall phenomenon

Catherine Droitcourt¹, H el ene Le H o², Henri Adamski¹, Fran ois Le Gall³ & Alain Dupuy¹

¹Department of Dermatology, Pontchaillou Hospital, Rennes, France, ²Department of Pneumology, Pontchaillou Hospital, Rennes, France and ³Pathology Department, Pontchaillou Hospital, Rennes, France

Abstract

Key words:

docetaxel; photo-recall; taxanes

Correspondence:

Dr Catherine Droitcourt, M.D., Dermatology
Department, Pontchaillou Hospital, 2 rue Henri le
Guilloux, 35000 Rennes, France.
Tel: +33 2 99 28 43 49
Fax: +33 2 99 28 41 00
e-mail: catherine.droitcourt@gmail.com

Accepted for publication:

2 April 2012

Conflicts of interest:

None declared.

Financial disclosure:

None reported.

Photo-recall phenomenon is a phototoxic eruption occurring on areas of previous ultraviolet (UV)-induced solar erythema following a systemic administration of a drug. It has been mostly described with methotrexate but remains rare with other antineoplastic drugs. We describe a case of docetaxel-induced photo-recall.

A 63-year-old woman presented to our department in February 2011 with an acute rash on sun-exposed areas. She was being treated for a metastatic non-small-cell lung cancer diagnosed in July 2010. Progression occurred despite cisplatin and erlotinib, and docetaxel was introduced in February 2011. She had not had radiotherapy. At day 3 after the first infusion of docetaxel at standard dosage of 75 mg/m², she presented with an intense erythematous rash strikingly distributed on photoexposed areas: the head; the posterior aspect of the hands, forearms, and feet; the trunk; and the lower neck (Fig. 1a–c). No bullous lesion was observed, the mucous membranes were uninvolved, and she tolerated well her condition with no fever. A skin biopsy revealed necrotic keratinocytes in the basal layer of the epidermis and a lymphocytic infiltrate around the small dilated vessels of the mid-dermis. There was no vasculitis (Fig. 1d). Other medications within the 2 weeks preceding the rash included methylprednisolone and ondansetron administered with docetaxel. The

Photo-recall phenomenon is a phototoxic eruption occurring on areas of previous ultraviolet-induced solar erythema following a systemic administration of a drug. It has been mostly described with methotrexate but remains rare with other antineoplastic drugs. We describe a case of docetaxel-induced photo-recall skin rash in a woman treated for a non-small-cell lung cancer. Although the patient has refused to receive a second infusion, chemotherapy can be carried on with photoprotection and the use of topical and/or systemic corticosteroids. In contrast, radiation recall is a well-known reaction by oncologists, most of them may not be aware of a similar phenomenon called photo-recall phenomenon. Recognizing this entity may avoid misdiagnosing a drug allergy and should avoid inappropriate decisions of drug discontinuation.

patient denied being exposed to UV radiation during the past 3 days. However, she was returning from a trip in the French West Indies, where she had moderate sunburn the day before taking her flight, i.e. 2 days before docetaxel administration. This sunburn did not lead to skin bullae and was unnoticed the day she received docetaxel. We diagnosed a docetaxel-induced photo-recall phenomenon. The recall eruption was much more intense than the initial sunburn and resolved within 2 weeks with potent topical corticosteroids (bethametasone cream once a day). The patient refused to carry on docetaxel, and the drug was not rechallenged.

The term 'photo-recall' has been proposed by similarity to the 'radiation-recall' phenomenon (1, 2). Other terms referring to the same entity, include UV recall, sunburn recall, or photo-dermatitis reactivation. The photo-recall phenomenon is characterized by a drug-induced skin rash located on a previously sunburned area. The rash occurs between 1 and 8 days after the sunburn and between 1 day and 1 week after drug administration (1). Skin rashes occurring several months after the sunburn have been suspected but are difficult to ascertain. The rash usually does not recur at drug rechallenge (3, 4). Topical and/or systemic corticosteroids may help if early rechallenge is necessary.

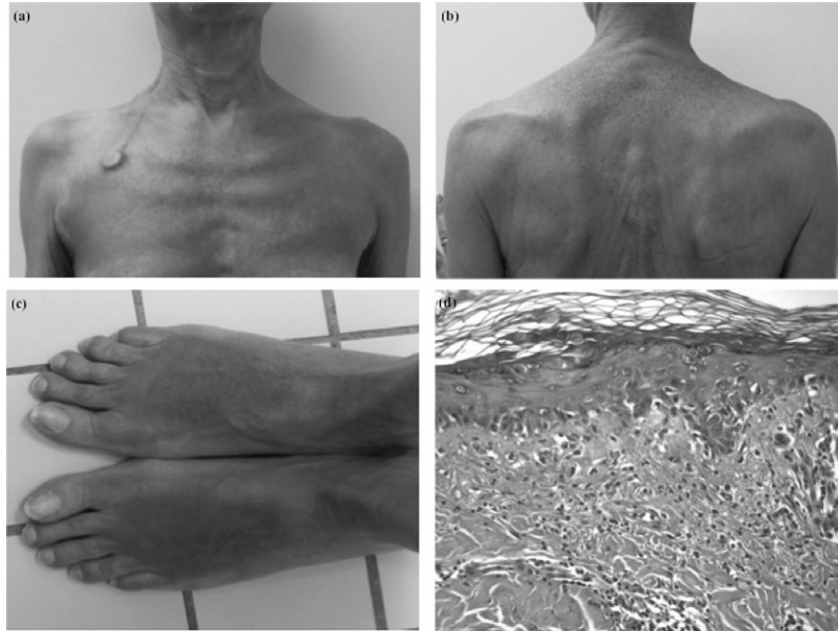


Fig. 1. Photodistributed rash at day 3 after docetaxel infusion (a, b, c). Histology: necrotic keratinocytes in basal membrane and lymphocytic infiltrate. Hematoxylin-eosin. Magnification $\times 20$ (d).

Photo-recall phenomenon has been mostly described with methotrexate but remains rare with other antineoplastic drugs. Few cases have been documented with gemcitabine, etoposide, cyclophosphamide, suramin, and paclitaxel (1, 3, 4). Various antibiotics including piperacillin, tobramycin, ciprofloxacin, gentamicin, and cefalozin have been also reported as photo-recall drug inducers (5).

Docetaxel is of the taxane group of chemotherapy drugs and is a semi-synthetic analogue of paclitaxel. Only one previous case with paclitaxel has been reported with the same delay as in our case (3 days).

The pathophysiology of photo-recall phenomenon is still unclear. After a sub-erythematous exposure to UV light, the drug might upregulate UV-dependent pro-inflammatory factors, and thus reaching the erythematous threshold. This hypothesis might explain the recall reaction.

We believe the photo-recall phenomenon is worth being known in order to correctly interpret this peculiar type of eruption occurring after drug administration. Because antineoplastic

drugs are among the most-reported drugs, dermatologists and oncologists should specifically be aware of this phenomenon. In most cases, drug rechallenge can be safely proposed.

References

1. Goldfeder KL, Levin JM, Katz KA, Clarke LE, Loren AW, James WD. Ultraviolet recall reaction after total body irradiation, etoposide, and methotrexate therapy. *J Am Acad Dermatol* 2007; **56**: 494–499.
2. Camidge R, Price A. Characterizing the phenomenon of radiation recall dermatitis. *Radiother Oncol* 2001; **59**: 237–245.
3. Badger J, Kang S, Uzible A, Srinivas S. Double diagnosis in cancer patients and cutaneous reaction related to gemcitabine: case 3. Photo therapy recall with gemcitabine following ultraviolet B treatment. *J Clin Oncol* 2005; **23**: 7224–7225.
4. Ee HL, Yosipovitch G. Photo recall phenomenon: an adverse reaction to taxanes. *Dermatology* 2003; **207**: 196–198.
5. Krishnan RS, Lewis AT, Kass JS, Hsu S. Ultraviolet recall-like phenomenon occurring after piperacillin, tobramycin, and ciprofloxacin therapy. *J Am Acad Dermatol* 2001; **44**: 1045–1047.